

External Trauma and Dental Implant Treatment

Rei Nakasawa, Hiroshige Shintani, Hiromiti Takubo, and Tatsuo Haruoka

AI DentalClinic, Matsuoka Build. 4F., 1-13-17 Higashi Hakata Eki, Hakata-Ku, Fukuoka 812-0013, Japan

A meticulous plan is essential to conduct implant treatment for defects caused by trauma. Since it is impossible to move the position of an established implant, a three-dimensional treatment plan based on CT diagnostic imaging is extremely important for implant treatment especially in the growth phase or combined with orthodontic treatment. Currently, dental CT used in corrective diagnosis has been applied to clinical dentistry, and high-level imaging studies have become widely practiced (Fig. 1, 2 and 3). In addition, in the case of invasion and defect involving also the alveolar bone as a result of trauma, various softwares are now available for three-dimensional diagnosis (Fig. 4 and 5) and implant planning as a support for the overall prosthetic and surgical treatment plans. The environment and work flow of the treatment procedures are introduced (Fig. 6).

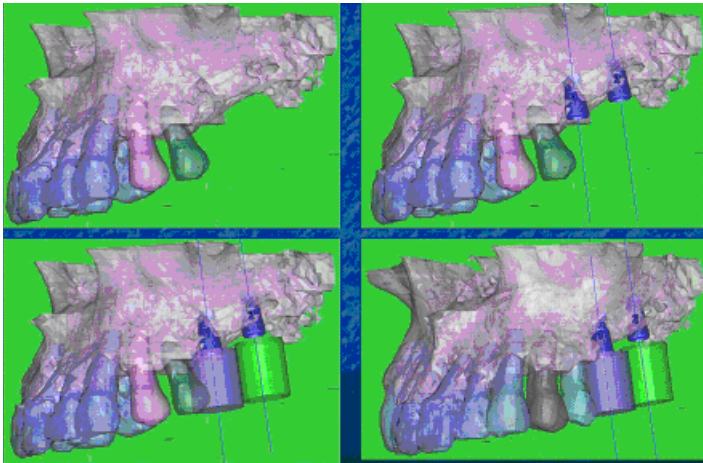


Fig.1 SimPlant Dental displacement based on 3-dimensional imaging diagnosis and implant placement

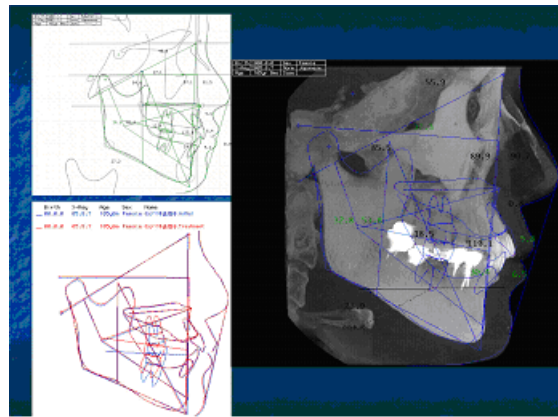


Fig.2




Fig.3 Preoperative diagnosis of an example reduced by implant anchor Predictive Simulation after reduction

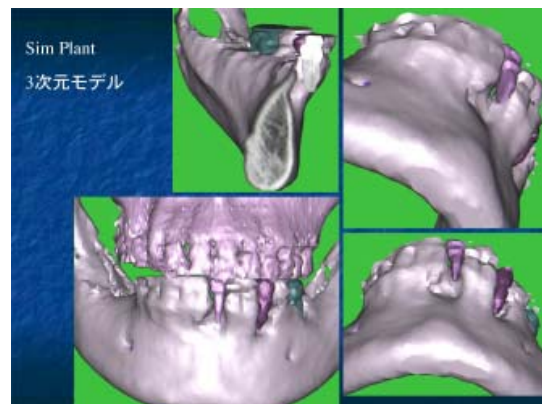


Fig. 4

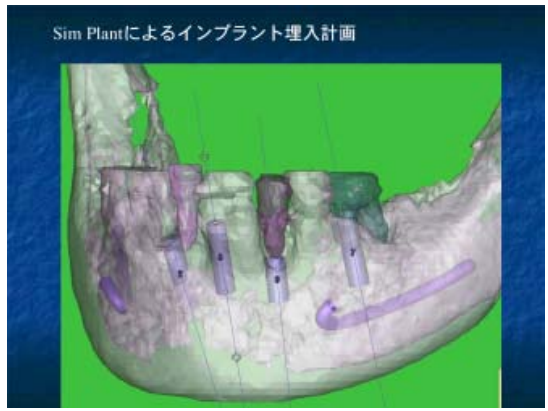


Fig. 5

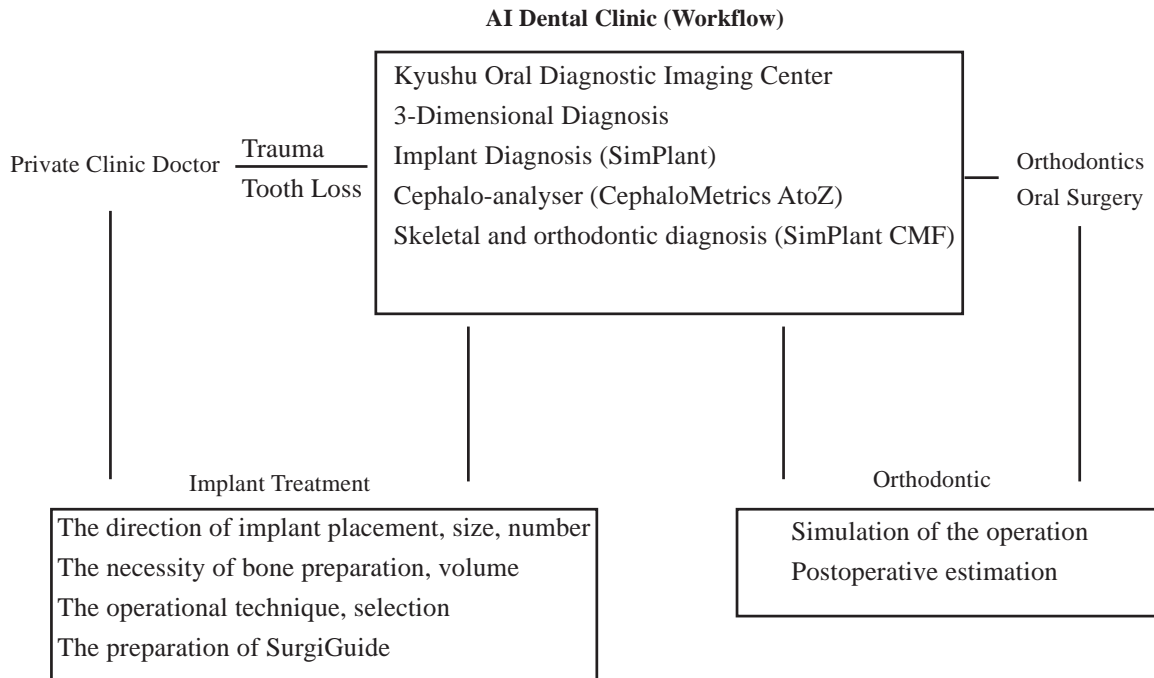


Fig. 6