

A Long-term Follow up Case of Complete Luxation of Primary Central and Lateral Incisors

Yukako Nakauchi, Mizuki Onojima, Kenji Arita, and Mizuho Nishino

Department of Pediatric Dentistry, Social and Environmental Medicine
Integrated Sciences of Translational Research, Institute of Health Biosciences
The University of Tokushima Graduate School

Introduction

Replantation is generally considered to be contraindication for a traumatic complete luxated primary tooth. Because it tends to cause growth disorder and exchange disorder in the successive permanent teeth. And because it tends to have poor prognosis due to low cooperation during treatment of fixation in very young infant, in whom complete luxation occurs more frequently than the other age. Then there are a few reports about replantation of primary tooth.

A comprehensive diagnosis and a treatment skill are very important in a young patient who visits the dentist for a treatment of traumatic injury, because that the prognosis of replantation and a normal stomatognathic growth may not be assured after the luxated teeth were replanted.

In this case report, the replantation of four complete luxated lower primary teeth was followed by correction of anterior cross-bite, extraction of impacted supernumerary mesiodens and observation until eruption of the successive permanent teeth during 7 years and 3 months.

A case report

Patient:

1-year-and-9-months-old female (at first visit)

Chief complaint:

A traumatic injury of mandibular anterior teeth

History of the present injury:

The patient fell down from the second floor of her home, and injured mandibular anterior teeth. She visited a nearby dental clinic and was referred to the University Hospital. She visited our clinic one and a half hours after trauma.

Findings at first visit:

Complete luxation of BA AB, an alveolar bone fracture, lacerated gingival wound (Figure 1,2), erupted teeth $\frac{04b}{04d}$, an anterior cross-bite

Treatment at first visit:

Under local infiltration anesthesia, BA AB were replanted, gingiva was sutured, and luxated teeth were fixed with a chemically cured composite resin of low viscosity. Impression

was taken with alginate and a plastic splint was made with ERKOFREX® and ERKOPRESS®. A plastic splint was set in the patient with non-eugenol periodontal dressing, COE-pak® (Figure 3).

Progress:

All fixations were removed at 24 days after injury. And regular observations were continued at every 3-6 months until the eruption of successive permanent teeth. Light mobility and extrusion was observed on A at removal of fixation, but the other teeth were not observed abnormal mobility.

For avoiding external force to traumatic teeth by anterior cross-bite, an upper dental arch was expanded with a removable appliance with expansion screw at 2-years-and-9-months-old (one year after injury) (Figure 4). Anterior cross-bite became normal

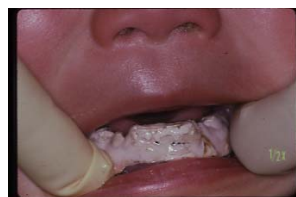

Fig.3

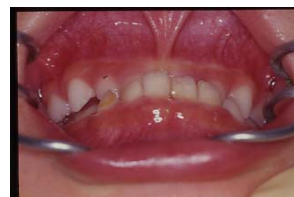

Fig.4

occlusion about 5 months later.

Radiolucency around the root apex of A was recognized on the dental X-ray at 1 year and 8 months after injury, so the root canal treatment and filling with Vitapex® were done.

Impacted supernumerary mesiodens between A A was discovered on the dental X-ray at 3-years-and-0-month-old (Figure 5). Supernumerary mesiodens was extracted under infiltration anesthesia at 5-years-and-2-months-old.

At 5-years-and-6-months-old, A had shed naturally, and A was extracted at this time. 1 1 erupted at 5-years-and-8-months-old, and abnormal crown form was found on the dental X-ray (Figure 6). Enamel hypoplasia were observed on labial side of 1 1 (Figure 7). 2 2 erupted at 8-years-and-7-months-old, didn't show enamel hypoplasia.

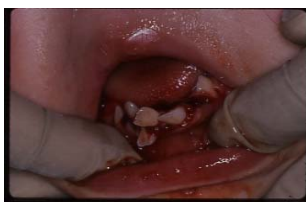

Fig.1

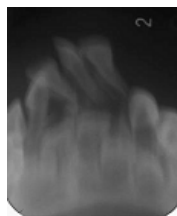


Fig.2

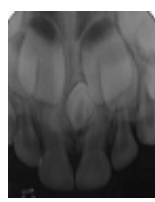


Fig.5

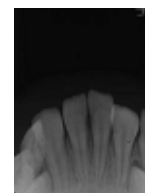


Fig.6

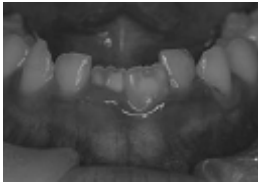


Fig.7

For 7 years and 3 months after injury, the patient gradually got a normal stomatognathic growth.

Discussion

The present case shows that the replantation of primary tooth has good prognosis under careful observation if a complete luxated tooth has good condition. An obstacle of successive permanent teeth such as hypoplasia is often occurred. It is supposed that an obstacle arises from damage of injury and has nothing to do with replantation. Replantation of complete luxated primary tooth is worth for a normal development of permanent dentition including functional and aesthetic improvement. It is not quite exceptive for a traumatic injured patient that pediatric dentists should do a long-term follow up to obtain a normal stomatognathic growth including occlusal guidance.