

A Study of Eight Oral Malignant Melanoma in Adults by WESTOP (Western Society of Teachers of Oral Pathology, 1995)

Kenji Kawahara¹⁾, You-jin Lee¹⁾, Hitoshi Nagatsuka¹⁾, Kan Rui²⁾, Elza Ibrahim Auerkari³⁾,
Ma C. G. Z. Floresca⁴⁾, Hiroshi Kishikawa⁵⁾, and Noriyuki Nagai¹⁾

¹⁾Okayama University, Graduate School of Medicine, Dentistry and Pharmaceutical Sciences

²⁾Dental Titanium Giken, Okayama

³⁾Univ. of Indonesia, Dept. of Oral Biology, Indonesia

⁴⁾Dela Salle Univ., Dept. of Chemistry, Philippine

⁵⁾Japan Institute for Advanced Dentistry, Osaka

Introduction

Primary oral mucosal melanoma is an extremely rare tumor. The aggressive behavior of the tumor together with other factors worsens the prognosis. The absence of standardized treatment protocol also contributes to the decrease in the survival rate. Eight human oral mucosal melanoma cases were evaluated clinically and histopathologically. Results revealed that even a surgical margin of 2 cm might contain atypical melanocytic proliferation, which may increase the risk of local recurrence. In addition to this, events of skip lesions and an increase in thickness of the tumor may also contribute to the risk of local recurrence. These suggest that oral mucosal melanoma's prognostic factors are different from that of cutaneous melanoma and oral mucosal melanoma has a more aggressive behavior than its cutaneous counterpart. This study was to evaluate the clinical and histopathological findings of oral mucosal melanoma. Furthermore, the surgical margins were likewise assessed and correlated to the prognosis of the tumor.

Material and Methods

Eight cases were retrospectively examined; seven cases of oral mucosal melanoma and 1 case of lentigo maligna melanoma. The clinical features, histopathological findings and presence of recurrence were compiled and summarized (data not shown). Selected hematoxylin and eosin sections were used to examine and classify the tumors based on the proposed Western Society of Teachers of Oral Pathology (WESTOP) nomenclature¹⁾. The tumor thickness was measured (except for lentigo maligna melanoma) using a micrometer. Tumors with intact epithelium were measured starting from the layer where atypical melanocytes were observed to the greatest depth of the tumor cell penetration. When ulceration was present, the measurement was made from the ulcerated surface to the greatest depth of the tumor. Surgical operation tissues were selected, evaluated and plotted microscopically using the following abbreviations: N – normal epithelium, 1 – with atypical melanocytic hyperplasia at the epithelium limited to the basal layer without underlying lymphocytic reaction, 2 – in situ melanoma (with pleomorphic, large, irregular and hyperchromatic nuclei in a pagetoid spread), 3 – invasive melanoma. Regional lymph node metastasis and local recurrence were also noted.

Result

All cases occurred on the hard palate and maxillary gingiva. Age ranges from 58 – 79 years and gender distribution is equal. Two cases were amelanotic and five were melanotic. The cases were histologically classified following the WESTOP

nomenclature¹⁾. The lentigo maligna melanoma was categorized as in situ oral mucosal melanoma (Fig. 1), 7 cases were classified as invasive oral mucosal melanoma. Out of these 7 cases, 6 cases had in situ component (invasive oral mucosal melanoma with in situ component). Histopathological examination of tumor cells in invasive oral mucosal melanoma and invasive oral mucosal melanoma with in situ component revealed the presence spindle and epithelioid cells or both cells present in one tumor. The tumor cells were arranged in nodular or sheet-like architectures. Mitotic figures and vascularization of the tumor were observed and necrosis was hardly noticed from the sections.

Cases were also classified based on the clinical staging. Three cases were in stage I (localized without lymph node metastasis) and 5 cases were in stage II (with regional lymph node metastasis). Tumor thickness ranged from 1.2 mm to 10 mm. Recurrence was also noted. In stage I, two cases had (except for lentigo maligna melanoma) and in stage II, 3 cases had recurrence.

All cases were surgically removed with at least 2 cm margin on a normal mucosa clinically. The entire surgical tissues were microscopically evaluated and specific areas, as mentioned in materials and methods, were plotted. Microscopically, in situ oral mucosal melanoma had all surgical margins free from atypical melanocytes. All other cases (invasive and invasive with in situ) had mostly normal and clear margins with rarely atypical melanocytes. Three cases were observed to have skip lesions (Fig. 2).

In conclusion, we suggest that the WESTOP nomenclature may be useful in histologically classifying oral mucosal melanoma separately from cutaneous melanomas. The presence of skip lesions, atypical melanocytic proliferation within the surgical margin and an increase in thickness of the tumor may augment local recurrence rate. With these factors, local failure is difficult to control. Oral mucosal melanoma's prognostic factors are different from that of cutaneous melanomas and oral mucosal

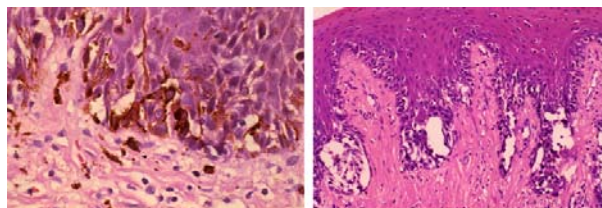
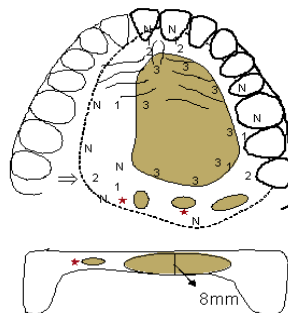
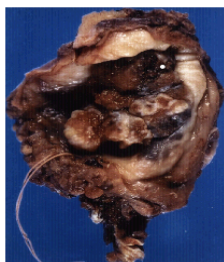


Fig1. The different type melanocyte proliferates in the epithelium. The cell projection is extended, and it moves in the epithelium. The different type melanocyte proliferates in the group in the cuticle nipple layer and it exists as a bright part. However, the different type melanocyte has not permeated in the organization of uniting under the epithelium.

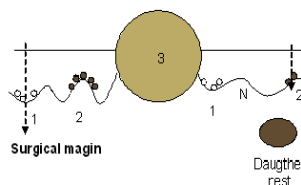
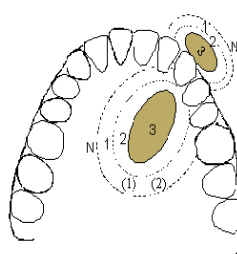
Invasive oral mucosal melanoma with in situ component



75, male
Metastasis in lymph node
After 1 year relapse in oral plate

- *Normal area (N)
- * In situ oral mucosal melanoma (early melanoma area) (1)
- * Invasive oral mucosal melanoma (2)
- * Invasive oral mucosal melanoma with in situ component(3)

Summary



- I. The focus is chiefly generated in the palate and gums, and has the tendency to cause in frequent occurrence.
- II. Histology finding is some surgical margins contained atypical melanocytes.
- III. Skip lesions were detected near the surgical margins.

melanoma has a more aggressive biologic behavior than its cutaneous counterpart. Indeed, the earnest way to improve survival rate is through early diagnosis. The identification of precursor melanotic lesions will likewise improve survival rate. Definitely, there should be more and beyond to achieve toward the prevention of this malignancy.

Reference

1. Barker BF, Carpenter WM, Daniels TE, Kahn MA, Leider AS, Lozada-Nur F, Lynch DP, Melrose R, Merrell P, Morton T, Peters E, Regezi JA, Richards SD, Rick GM, Rohrer MD, Slater L, Stewart JC, Tomich CE, Vickers RA, Wood NK, Young SK. Oral mucosal melanomas: the WESTOP Banff workshop proceedings. *Western Society of Teachers of Oral Pathology. Oral Surg Oral Med Oral Pathol Oral Radiol Endod* 83:672-9,1997
2. Garzino-Demo P, Fasolis M, Maggiore GM, Pagano M, Berrone S. Oral mucosal melanoma: a series of case reports. *J Craniomaxillofac Surg* 32:251-7,2004
3. Rapidis AD, Apostolidis C, Vilos G, Valsamis S. Primary malignant melanoma of the oral mucosa. *J Oral Maxillofac Surg* 61:1132-9,2003
4. Medina JE, Ferlito A, Pellitteri PK, Shaha AR, Khafif A, Devaney KO, Fisher SR, O'Brien CJ, Byers RM, Robbins KT, Pitman KT, Rinaldo A. Current management of mucosal melanoma of the head and neck. *J Surg Oncol* 83:116-22,2003
5. Tanaka N, Mimura M, Ogi K, Amagasa T. Primary malignant melanoma of the oral cavity: assessment of outcome from the clinical records of 35 patients. *Int J Oral Maxillofac Surg* 33:761-5,2004
6. Prasad ML, Busam KJ, Patel SG, Hoshaw-Woodard S, Shah JP, Huvos AG. Clinicopathologic differences in malignant melanoma arising in oral squamous and sinonasal respiratory mucosa of the upper aerodigestive tract. *Arch Pathol Lab Med* 127:997-1002,2003
7. Lopez-Graniel CM, Ochoa-Carrillo FJ, Meneses-Garcia A. Malignant melanoma of the oral cavity: diagnosis and treatment experience in a Mexican population. *Oral Oncol* 35:425-30,1999
8. Nagatsuka H, Santos Rivera R, Gunduz M, Lee YJ, Tamamura R, Gunduz E, Naito I, Sado Y, Nagai N. Immunolocalization and distribution patterns of type IV collagen alpha chains in oral mucosal melanoma. *Virchows Arch* 27:1-7,2005
9. Prasad ML, Patel SG, Huvos AG, Shah JP, Busam KJ. Primary mucosal melanoma of the head and neck: a proposal for microstaging localized, Stage I (lymph node-negative) tumors. *Cancer* 100:1657-64,2004
10. Regezi JA, Hayward JR, Pickens TN. Superficial melanomas of oral mucous membranes. *Oral Surg Oral Med Oral Pathol* 45:730-40,1978
11. Lengyel E, Gilde K, Remenar E, Esik O. Malignant mucosal melanoma of the head and neck. *Pathol Oncol Res* 9:7-12,2003
12. Tanaka N, Amagasa T, Iwaki H, Shioda S, Takeda M, Ohashi K, Reck SF. Oral malignant melanoma in Japan. *Oral Surg Oral Med Oral Pathol* 78:81-90,1994