

Supernumerary Teeth are Useful for Immediate Auto-tooth Transplantation.

Shuichi Tsubura, Tsunetoshi Kumakubo

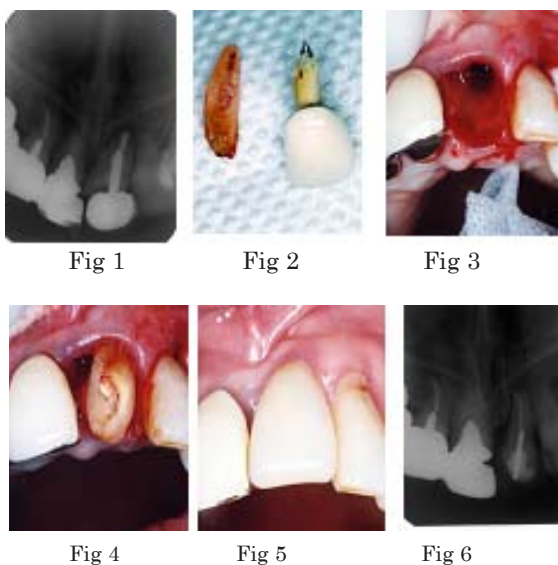
Tsubura dental clinic, 9-6 Enomachi , Tochigi , 320-0802,Japan.

Introduction

On the rebuilding strategy after traumatic tooth loss, “Crown & Bridge”, “Dental Implant”, “Partial Denture”, and “Auto-tooth Transplantation” have been applied. Among them, auto-tooth transplantation for replacement is supposed to be biologically superior method to other treatments, but auto-tooth transplantation has been scarcely selected as the first choice. Although many technical methods of auto-tooth transplantation have been introduced for replacement of traumatic tooth loss, problems such as selection of donor tooth and postoperative root resorption still remain to promote auto-tooth transplantation. In the selection of donor tooth, the supernumerary tooth or the microdont tooth is supposed to be better than wisdom tooth. Since the front teeth were lost in many traumatic tooth loss, the space of recipient site is not enough for replacement by a wisdom tooth. We showed two rebuilding cases after traumatic tooth loss by the transplantation using supernumerary or microdont tooth.

(Case 1) 67yrs female

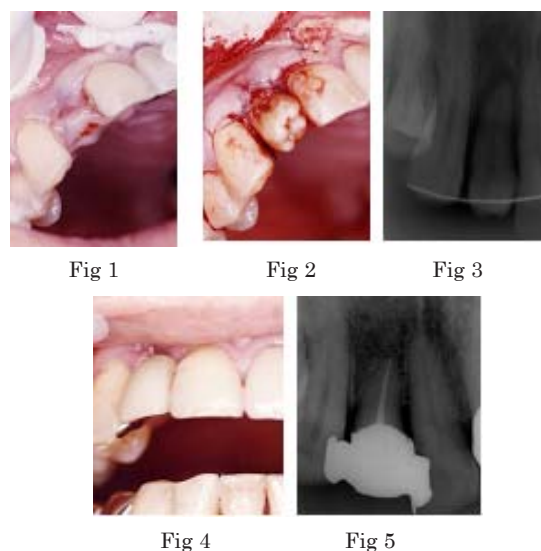
The immediate transplantation was performed using a supernumerary tooth. Patient fell down and hurted upper front teeth, and was treated at Tsubura Dental clinic. After three hours , left side upper incisal teeth already root fractured (Fig 1) and post crown has fell down (Fig 2). We extensively discussed and decided to rebuild by auto-tooth transplantation using a supernumerary tooth standing alongside left side upper premolar teeth. Transplantation was performed as follows; extraction of traumatic tooth was done (Fig 3) and a supernumerary tooth was immediately transplanted (Fig 4). After six weeks, root canal filling was finished and post core and temporary crown were built up. After eight weeks, final restoration was done such as impression and adhesion for the new crown (Fig 5). X-ray photograph was taken to check the condition of three years after transplantation(Fig 6).



(Case 2) 58yrs male

After one month of traumatic tooth loss, transplantation was done using a microdont wisdom tooth. Patient hurted on the upper right side lateral incisor teeth, which was extracted at emergency hospital in Utsunomiya city. After one month(Fig 1), patient come to the Tsubura Dental clinic decided and was administered rebuilding by an auto-tooth transplantataion using an upper left side microdont wisdom tooth.

A microdont wisdom tooth was transplanted(Fig2,3). After four weeks, root-canal filling was done and built up post core and temporary crown. After eight weeks, final restration was done such as impression and adhesion for the new crow & bridge(Fig 4). Fig 5 is a status of three years later x-ray photograph after transplantation was done.



In the future

We presented these cases to show the possibility of rebuilding using auto-tooth transplantation, when any suitable donor tooth is conserved, auto-tooth transplantation is convenient and useful technique for replacement of traumatic tooth loss. Especially the supernumerary tooth and microdont tooth are suitable for rebuilding on account of a single root and a compact size. Many of supernumerary teeth and of microdont teeth are destined to be extracted at the early stage in spite of the environment and the condition are good, however we propose it is better to preserve these special teeth as much as possible. Otherwise, there is uncertainty on the prognoses of the donor tooth. To investigate these problems, it is necessary to accumulate clinical data and to establish clinical techniques good for the rebuilding strategy of the traumatic tooth loss.