

Replantation of an Avulsed Primary Central Incisor

Shuhei Kubo, Mari Kadoya, Tomoko Takeuchi, Masashi Yakusiji

Department of Pediatric Dentistry, Tokyo Dental College, Japan

Abstract: Although replantation of avulsed primary teeth is described as a contraindication in some books, there have been reports that patients had uneventful courses after replantation of avulsed primary teeth until eruption of the succeeding permanent teeth. We replanted an avulsed primary central incisor and followed up the patient until eruption of the succeeding permanent incisor. The patient was a boy aged 2 years and 1 month old at the initial visit. He fell from a chair and hit the maxillary incisor region. At the injury, the right primary central incisor was avulsed, and the patient came to the clinic after preserving the lost tooth in milk. Since the patient's parent strongly wished replantation of the tooth at the initial visit, we carefully explained the risk of infection after replantation, obtained the parent's consent, and replanted and splinted the tooth. No particular adverse clinical problems were observed during the follow-up period, and the succeeding permanent tooth erupted nearly at its normal position.

Key words : Replantation, Avulsion, Primary teeth, Succeeding permanent teeth

Introduction

The number of patients with a chief complaint of traumatized teeth is increasing in our clinic. Among all patients who visited the Department of Pediatric Dentistry in Tokyo Dental College with a chief complaint of traumatized primary teeth in 2003, patients with avulsed primary teeth accounted for approximately 6%. Clinical guidelines for tooth avulsion due to trauma were proposed by the American Academy of Pediatric Dentistry (AAPD) and the International Association of Dental Traumatology (IADT). According to these guidelines, replantation is recommended when the avulsed teeth are permanent teeth, whereas replantation is contraindicated when the avulsed teeth are primary teeth, to avoid infection to the successional permanent teeth. However, there have been recent reports that a good clinical course was obtained after primary tooth replantation, and replacement with the permanent teeth was completed in the successional replacement period.

In this study, we reported a patient who was 2 years and 1 month old boy at the first visit, in who after replanting a maxillary primary central incisor avulsed due to trauma, course observation was performed until the eruption of the successional permanent tooth. Regarding the treatment and this report, informed consent was obtained from the patient's caretakers.

Case report

Patient: 2 years and 1 month old boy

First visit: July 15, 1998

Chief complaint: Avulsion of the maxillary right primary central incisor

Patient's history: The patient had no history of disorder.

Family history: His family members had no history of disorder.

Present illness: The patient fell down from a child chair at a restaurant at around 11:30 in the morning, July 15, 1998, and strongly struck the maxillary anterior tooth region on the floor. An employee of the restaurant noticed avulsion of a tooth, and immediately immersed the tooth in milk for preservation. The patient visited the Department of Pediatric Dentistry in Tokyo Dental College Chiba Hospital 1 hour and 30 minutes after injury.

Patient's consciousness was clear and vital signs were normal at the time of visit. Furthermore, no injury was found in the body other than the oral cavity. The avulsed maxillary right primary central incisor was brought to our department being preserved in

milk at room temperature. The alveolar socket of the avulsed tooth was filled with blood clot without bleeding. Neither tooth mobility nor positional abnormalities were detected in other teeth. Furthermore, no lacerated wound was present in the gingiva in the maxillary right primary central incisor area.

Fig. 1-a Shows the X-ray at the first visit. No clear fracture line in the alveolar bone in the maxillary right primary central incisor area was detected. The adjacent teeth showed neither the expansion of the periodontal ligament space nor root fracture. Formation of the approximately 1/2 of the tooth crown of the right permanent central incisor was confirmed. Furthermore, no clear positional abnormalities were found in the right permanent central incisor and adjacent permanent teeth.

Treatment at the first visit

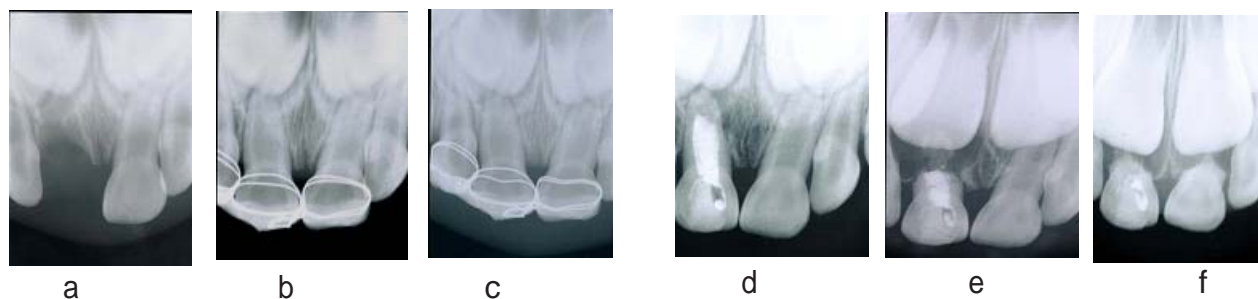
Before starting treatment, we sufficiently explained to the parents that there was a report that the replantation of the primary teeth is contraindicated, the risk of infection after replantation, and a treatment method in cases of infection. Simultaneously, we explained a treatment method without replantation. As a result, the parents requested replantation. Therefore, replantation of the avulsed tooth and splint were performed in the following procedures:

1. The alveolar socket of the avulsed tooth was irrigated with physiological saline.
2. The avulsed tooth preserved in milk was washed with physiological saline.
3. Immediately after washing, the tooth was inserted in the alveolar socket using fingers, and was stable in the alveolar socket, showing a good replantation condition.
4. Splint was performed using the adjacent teeth as the anchorage unit, and using orthodontic ligature wires and composite resin.

Fig. 1-b shows the X-ray immediately after splint. It was confirmed that the avulsed tooth was repositioned in the alveolar socket. After treatment, antibacterial agents and analgesics were administered, and we explained matters that require attention about diet and daily life.

Course

At the examination on the following day of the replantation, the patient had no pain, and the splint condition was good. Fig. 1-c shows the X-ray 19 days after replantation. No clear external



a : Before treatment (2 years and 1month old)

b:Replantation and splinted

c : 19 days after replantation

d :1 year and 1month after replantation (3 years and 2 month old) The root apical area was closed with hard tissue.

e : 2 years and 6 months after replantation (4 years and 7 month old)The root resorption was rapidly progressing.

f : 3 years after replantation (5 years and 1 month old)The progression of the root resorption of the replanted tooth was slow.The root resorption of the left primary central incisor rapidly progressed.

Fig1. Radiographic findings

Author	Case	Teeth	Extra-alveolar time (min.)	Root canal treatment	Follow-up (Months)	Prognosis
Shirase (2004)	1	A	60	○	80	Exfoliated, incisor
	1	A	30	×	27	During
	2	A	60	×	60	Exfoliated, Permanent incisor had white spots
	3	B	120	○	36	Exfoliated, Permanent incisor is normal
	4	A	N/A	×	2	Extraction due to abscess
	5	B	30	×	42	Extraction due to root
	6	AB	60	×	17	Extraction due to abscess
Tsukiboshi (2000)	I	A		15	×	46 Exfoliated Permanent incisor
Weiger (1999)	1	A	30	○	24	Extraction due to abscess Permanent incisor had discolouration

Table 1 .Case Reports of Replanted Primary Incisors

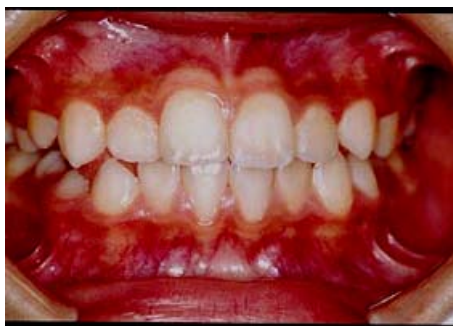

Fig2. Clinical findings at the age of 9 years and 1 month, Right permanent incisor had white spots of the labial Surface.

root resorption was detected. Furthermore, there were no X-ray images in which the resorption of the alveolar bone around the root was suspected. In this day, splint was removed, and the degree of tooth mobility was measured using a Dental Mobility Checker (Yoshida Co.). As a result, the degree of the mobility of the replanted maxillary right primary central incisor was 4.7, and that of the maxillary left primary central incisor was 3.3.

Since discoloration of the tooth was found 25 days after replantation, root canal treatment was started immediately, and

root canal filling was performed using a calcium hydroxide agent (Vitapex, Neo dental Chemical Products Co., Ltd.). Thereafter, the patient could not visit our clinic for 1 year due to his mother's second childbirth.

At the interview and examination after 1 year, it was confirmed that the patient was not having problems in his daily life. Since the replanted tooth showed metallic sound by percussion, osseous ankylosis was suspected. The degree of mobility of the tooth was 2.7. Fig. 1-d shows the X-ray 1 year and 1 month after replantation. A radioopaque image of the root canal filling materials was confirmed, and the root apical area was closed with hard tissue. Furthermore, no clear external resorption images of the replanted tooth were detected. No radiolucent images were observed in the surrounding alveolar bone. However, it seemed that the periodontal ligament space of the replanted tooth was slightly constricted compared with that of the right central incisor on the opposite side.

Fig. 1-e shows the X-ray 2 year and 6 months after replantation. The root resorption was rapidly progressing compared with the right central incisor on the opposite side. Furthermore, transparent images in the alveolar bone around the root were confirmed. However, no clear developmental abnormalities such as morphological disorders were noted in the successional permanent tooth. Since the patient had neither spontaneous pain nor pain during mastication without problems in his daily life, observation was continued.

The patient visited our clinic 3 years after replantation with a complaint of the mobility of the maxillary bilateral primary central incisors. Fig. 1-f shows the X-ray 3 years after replantation. The progression of the root resorption of the replanted tooth was slow during the period between 2 years and 6 months after replantation and 3 years after replantation. On the other hand, the root resorption of the left primary central incisor rapidly progressed during this period, showing no bilateral differences in the degree of root resorption. The cause of the root resorption of the left primary central incisor was judged to be physiological root resorption. Course observation was continued.

At the patient's visit 3 years and 6 months after replantation, since the teeth was further mobile, we explained that the replacement with the permanent tooth was near, and the course was observed.

The eruption of the bilateral permanent central incisor was confirmed 3 years and 8 months after replantation.

Fig. 2 shows the intraoral photograph at the age of 9 years and 1 month. No marked influence of the replantation on the successional permanent tooth was noted, and although white spots localized of the labial surface of the right central incisor were found, no substantial defect of hard tissue was present.

Discussion

When primary teeth are avulsed by injury, replantation has been contraindicated. However, there have been many reports of the replantation of the primary teeth, since studies on the healing of replanted teeth have been progressed, and because of strong request by caretakers. Table 1 is the summary of the course after replantation made from case reports of primary tooth replantation. Although there have been cases in which tooth extraction was performed due to marked root resorption after replantation, good courses were obtained without severe influence on the successional teeth in most cases. Regarding the application criteria of primary tooth replantation, Takagi reported the following conditions:

1. Injury to the periodontal tissue around the avulsed teeth is slight.

2. Presence of anchorage unit
3. Absence of injury to the successional permanent teeth by replantation is expected.

Furthermore, other conditions influencing the application of replantation are the duration between injury and replantation and preservation methods of the avulsed teeth between avulsion and replantation. In our patient, injury to the periodontal tissue around the avulsed tooth was slight, and both of the teeth adjacent to the avulsed tooth could be used as the anchorage unit without clear injury. Furthermore, the duration between injury and replantation was 90 minutes, which was a comparatively short time, and the avulsed tooth was brought to our clinic, being preserved in milk immediately after injury. We considered that these good conditions caused a good course after replantation, without severe influence on the successional permanent tooth.

Our results in this study suggested that although it is inappropriate to recommend replantation in all avulsed primary tooth cases, replantation can be selected as a treatment guideline when conditions are good and the patient's caretakers' consent was obtained after sufficient explanation. However, it is necessary to determine application cases considering that primary tooth replantation is basically contraindicated according to the clinical guidelines in the AAPD and the IADT.

References

- 1) Shirase T, Kuroda A, Kawakami T, Ogata K, Sakayori H, and Uchikawa Y : Case of operation of a replantation of a deciduous tooth, *Jap J Pediatric Dent*, 42: 561-568,2004.
- 2) Kinoshita S, Mitomi T, Taguchi Y and Noda T : Prognosis of replanted primary incisors after injuries, *Endod Dent Traumatol*, 16:175-83,2000.
- 3) Tsukiboshi M: Trauma to the primary dentition. In: Tsukiboshi M, editor. *Treatment Planning for Traumatized Teeth*. Carol Steam: Quintessence Publishing; 2000. p. 105-16.
- 4) Weiger R. and Heuchert T : Management of an avulsed primary incisor, *Endod Dent Traumatol* , 15:138-43,1999.