

Clinical Study of Immediate Loading of JIAD(KOM) Implants in Partially Edentulous Jaws

Yueling Li¹⁾, Bo Sun¹, Ming chen¹⁾, Qui Kan²⁾, Noriyuki Nagai³⁾

¹⁾ Oral Department of Anting Hospital in ShangHai, China 201805

²⁾ Dentale Titanium GIKEN Co, Ltd. Japan

³⁾ Graduate School of Medicine, Dentistry and Pharmaceutical Sciences, Okayama University, Okayama, Japan

Abstract: The present study was undertaken to determine the feasibility of using primary stability as a predictor of implant success the short-term clinical result of treatment. **Methods:** This study included 32 patients, in whom a total of 80 implants were placed, 34 in maxillary sites and 46 in mandibular sites. Who were partially edentulous. From May 2001 to June 2004. All implants were immediately loaded in partially edentulous patients. Then, Within 2 hours providing support for fixed provisional prosthesis and noble-metal-ceramic crowns were completed with in 3 months. All patients were followed up by 1.3.6.12 months and after the patients were checked every 6 months. **Results:** There were no surgical complications. A total of 80 implants were loaded immediately, From May 2001 to June 2004, No implants were lost during follow-up (range 5-36 months, mean of 19 months), no infections, nerve or sinus damages or other accidents occurred. No implants exhibited peri-implant radiolucencies. Moreover, immediate loading seems to increase the ossification of the alveolar bone around endosseous implants. Patients were satisfied with the treatment. **Discussion:** Clinical research has shown that immediate loading is a viable treatment modality. The favorable success rate reported in this study for rough-surfaced implants suggests that adherence to a protocol, an important parameter of which is primary stability above 32 cm, can lead to osseointegration. **Conclusion:** The results of this limited investigation suggest that patients who are partially edentulous may be immediately restorations, Provided that the dental implants are adequately stable immediately after their surgical placement. The experience described in this study indicate that immediate loading with restorations using appropriate surgical and restorative techniques with one-stage JIAD(KOM) implant system can predicate the partially edentulous mandible in some cases. Further study is needed to determine the long-term result of immediately loaded implants.

Key words: Dental implantation; JIAD(KOM); Synostosis; Immediate loading.

The high success rates reported in a number of clinical studies have established dental implants as a predictable treatment modality in oral rehabilitation, provided that a number of parameters are given careful consideration [1,2]. A healing period of 3 to 6 months during which the implant is kept free of functional loads was once considered a prerequisite for the achievement of osseointegration. This healing period is convenient to the patient and may necessitate the fabrication of provisional restorations that are not supported by dental implants. The results of studies immediate loading appear encouraging. These techniques can assist the clinician in overcoming esthetic and functional problems during the healing period. Other clinical trials have reported on immediate loading of implants in completely and partially edentulous mandibles and maxillae [3,4].

The purpose of the present study was to describe immediate loading in both partially edentulous patients, using a protocol with particular emphasis on primary stability of the endosseous implant and provisional restorations that did not include rigid metal reinforcement.

Materials and Methods

In this clinical study 80 implants were placed in 32 patients, ranging in age from 16 to 72 years and female were 13 patients and man were 19 patients. All patients were partially

edentulous in both arches. All implants were loaded with temporary crowns within 2 hours. The distribution of implants were 34 implants in maxilla 46 implants in mandible. the length of the implants were 8 -16 mm..

All implants were used with JIAD(KOM) implant system in Japan. All of implant were one-stage, fabrication of pure titanium, without mucosal incision, taper screw type structure of V groove to prevent reverse rotation polishing of the neck region. All the restorations were removed after 3 months of function so that the implants could be examined. Criteria for failure [5] were defined as implant mobility, peri-implant radiolucency, or pain, discomfort, altered sensation, or infection attributable to the implants.

Results and Discussion

In this study, a total of 80 implants were placed in partially edentulous patients. All implants were loaded with temporary crowns within 2 hours and noble-metal-ceramic crowns after 3 months, and were followed for 1 or 3 years. There were no implant losses during either the healing period or the 3 year follow-up period. Radiographic evaluation of bone, which was performed at 3 months intervals postoperatively, revealed that the bone loss did not exceed the first screw thread of the implant. There were no hard or soft tissue complications.

The early investigations of Branemark, which eventually led to the application of dental implants, resulted in the establishment of an osseointegration protocol that included a submerged technique and a load-free postoperative healing period of 3 to 4

Correspondence to Oral department antinghospital China. Yueling Li E-mail: liyueling61@163.com Tel:0086-21-27183207 Fax:0086-21-59578086



Fig 1.JIAD(KOM) implant and drill

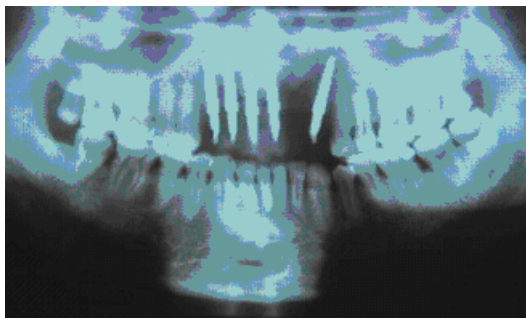


Fig.2. Panoramic radiograph of postsurgery

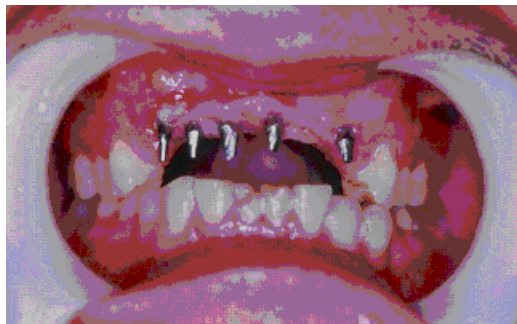

Fig.3. 5 implants placed in partial edentulous

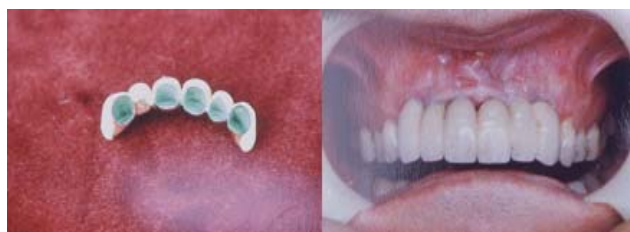

Fig.4. Restoration been made

Fig.5. Intraoral view of restoration

months for the mandible and 4 to 6 months for the maxilla[6].The 100% survival rate achieved in the present study may be attributed primarily to optimal initial stability and to the surface characteristics of the implants. Preparation of the osteotomy site to a width that was always smaller than the final implant diameter ensured primary stability even in poor quality bone.

Conclusions

The results of this limited prospective observational study indicate that immediate loading of implants may be a viable treatment option.

References

1) Buser D, Sutter F, Weber HP, Belser U, Schroeder A: The ITI Dental Implant System: Basis, indications, clinical procedures and results. In: Hadin J(ed). Clark's Clinical Dentistry. St Louis: Mosby, Vol 1:1-23,1992.

2) Buser D, Mericske-Stern R, Bernard JP, et al.: Long-term evaluation of nonsubmerged ITI implants. *Clin Oral Implants Res*, 8:161-172, 1997.

3) Cooper L F, Rahman A, Moriarty J, Chaffee N, Sacco D: Immediate mandibular rehabilitation with endosseous implants: Simultaneous extraction, implant placement, and loading. *Int J Oral Maxillofac Implants*, 17: 517-525, 2002.

4) Jaffin RA, Kumar A, Berman CL: Immediate Loading of implants in partially and fully edentulous jaws: A series of 27 case reports. *J Periodontol*, 71: 833-838, 2000.

5) Zarb GA, Albrektsson T. Towards: Optimized treatment outcomes for dental implants. *J Prosther Dent*, 80: 639-640, 1998.

6) Branemark P-I, Zarb G, Albrektsson T: *Tissue-Integrated Prostheses: Osseointegration in Clinical Dentistry*. Chicago: Quintessence, :11-17,1985.