

## A Retrospective Clinical Study of Loading of JIAD(KOM) Implants with Nature Teeth

Yulin Xie<sup>1</sup>, Yueling Li<sup>1</sup>, Zhichuen Pan<sup>1</sup>, Xueheng liu<sup>2</sup> Qi Ma<sup>2,3</sup>, Noriyuki Nakagi<sup>3</sup>

<sup>1</sup>.Oral Department of Anting Hospital in ShangHai China 201805

<sup>2</sup>.Oral Department of University of PeiKing China

<sup>3</sup>.Graduate School of Medicine, Dentistry and Pharmaceutical Science, Okayama University, Japan

**Abstract:**Background: Immediate implant function means great benefits for patients and therapists because treatment time and cost can be substantially reduced. The immediate-function JIAD(KOM) implant system have become an accepted alternative for fixed restorations in partial edentulous ,based on documented high success rates. Countinuous development is ongoing to fine simple protocols for their use. Purpose: The purpose of resent study was to develop and document a simple, safe and effective surgical and prosthetic protocol for immediate function (within 2 hours) of JIAD(KOM) implant system supporting fixed prostheses in partially edentulous patients. Materials and Methods: This retrospective clinical study included 7 patients with 16 nature teeth by immediately loaded implants, placed in the all region , supporting fixed complete-arch jaws.12 implants in 5 patients were placed in fresh extraction sites. The goal with the preparation and no mucosal incision and insertion technique was to achieve good primary implant stability and a minimum implant insertion torque of 30 Ncm before the implant was completely seated. The occlusion was adjusted to eliminate direct contact with the provisional prostheses. After 3 months, the patients received their permanent prostheses. All patients were followed for 1 year. Results: There were no implant losses in all sites. Conclusions: this therapeutic approach simplifies patient care without apparent additional risk.

**Key words:** Dental implantation; JIAD(KOM); nature teeth; Immediate loading.

The use of osseointegrated dental implants has made it possible to rehabilitate edentulous jaws . Immediate loading of implant-supported dental prosthese is documented with high and predictable success rates for the edentulous mandible.[1.2]. The challenge today is not to prove functionality but, rather, to develop simple and more using protocols. One such attempt is JIAD[KOM] components are premanufactured. The development of protocols for immediate loading has switched focus from the placing of several implants, of which some are submerged and included in without mucosal incision, immediately loading a few implants with nature teeth. The development to fewer implants is encouraged by the results from nature teeth load analyses, demonstrating that two implants and two nature teeth is an optimal number for complete-arch prosthesis provided they are placed as cornerstones all well spread If these implants are anchored optimally, the probability for success is high. The present protocol uses a simple guide for the best positioning and inclination of the implants, giving superior loading conditions for the implants and a simple technique.

The purpose of this article is to demonstrate the development of this curing nature teeth, and to present its clinical documentation. These techniques can assist the clinician in overcoming esthetic and functional problems during the healing period.Other clinical trials have reported on immediate loading of implants in completely and partially edentulous mandibles and maxillae[3.4].

### Materials and methods

Correspondence to Qi Ma. Peking University School of Stomatology 22 South Avenue Zhong Guancun Haidian District Beijing 10081P. RChina.Tel:+86-10-62173403.Fax:+86-10-62173402.E-mail: maqi64 @tom.com. National key Technologies R&D Program No 2004 BA 720 A25

In this clinical study 15 implants were placed in 7 patients,ranging in age from 21 to 56 years and female were 4 patients and man were 3 patients.All patients were partially edentulous in both arches. All implants were loaded with nature teeth by temporary crowns within 2 hous. The distribution of implants were 6 implants in maxilla 9 implants in mandible. the length of the implants were 13 -16 mm..All implants were used with JIAD(KOM) immplant system in Japan. All of implant were one-stage, fabrication of pure titanium, without mucosal incision, taper screw type structure of V groove to prevent reverse rotation polishing of the neck region. All the restorations were removed after 3 months of function so that the implants could be examined. Criteria for failure[5] were defined as implant mobility, peri-implant radiolucency, or pain, discomfort, altered sensation,or infection attributable to the implants.

One case to reporting:

### Results and Discusion

In this study, a total of 7 implants were placed in partially edentulous patients. All implants were loaded with nature teeth by temporary crowns within 2 hous and noble-metal-ceremic crowns after 3-5 months, and were followed for 1 years. There were no implant losses during either the healing period or the 3 year follow-up period. Radiographic evaluation of bone, which was performed at 3 months intervals postoperatively, revealed that the bone loss did not exceed the first screw thread of the implant. There were no hard or soft tissue complications. The early investigations of Branemark, which eventually led to the application of dental implants, resulted in the establishment of an osseointegration protocol that included a submerged technique and a load-free postoperative healing period of 3 to 4 months for the mandible and 4 to 6 months for the maxilla[6].The

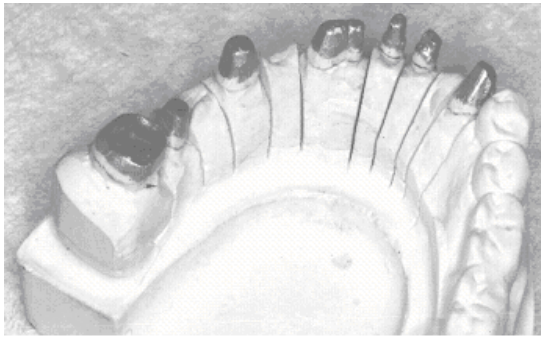


Fig 1. Panoramic radiograph of postsurgery



Fig 2. Intraoral view of surgery

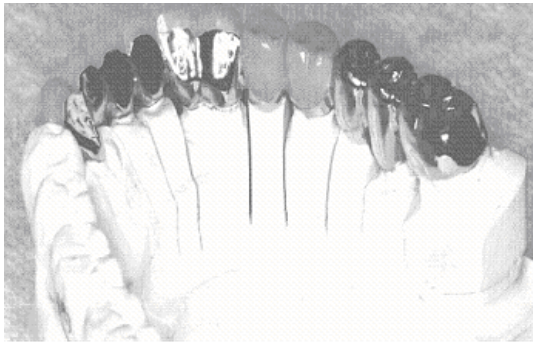

Fig 3. Retrospective been marking

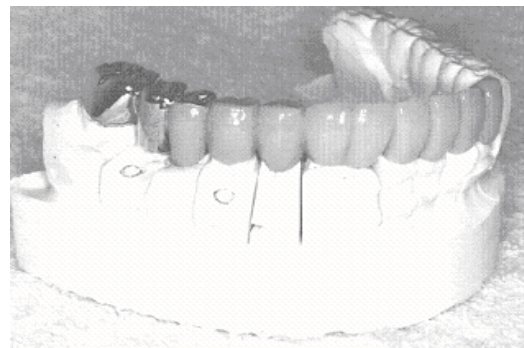


Fig 4. Retrospective been marking

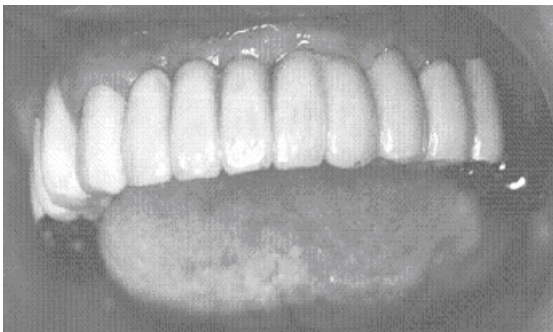

Fig 5. Noble-metal-ceramic

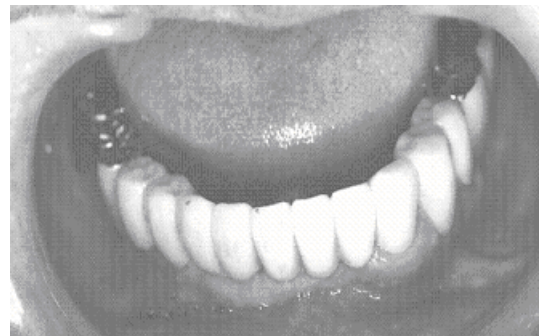

Fig 6. Noble-metal-ceramic

100% survival rate achieved in the present study may be attributed primarily to optimal initial stability and to the surface characteristics of the implants. Preparation of the osteotomy site to a width that was always smaller than the final implant implants were sured primary stability by nature teeth. It has been pointed out that implants in extraction sites are more sensitive to early losses at immediate loading, although this is not statistically significant[7].

### Conclusions

The results of this limited prospective observational study indicate that immediate loading of implants may be a viable treatment option and obtained primary stability with nature teeth.

### References

- 1) Balshi TJ, Wolfinger GJ: Immediate loading of Branemark implants in edentulous mandibles. A preliminary report. *Implant Dent*, 6: 83-88, 1997.
- 2) Ericsson I, Randow K, Nilner K, Peterson A: Early Functional

loading of Branemark dental implants:5-year clinical follow-up study. *Clin Implant Dent Relat Res*, 2: 70-77, 2000.

- 3) Cooper LF, Rahman A, Moriarty J, Chaffee N, Sacco D: Immediate mandibular rehabilitation with endosseous implants: Simultaneous extraction, implant placement, and loading. *Int J Oral Maxillofac Implants*. 17: 517-525, 2002.
- 4) Jaffin RA, Kumar A, Berman CL: Immediate Loading of implants in partially and fully edentulous jaws: A series of 27 case reports. *J Periodontol*, 71: 833-838, 2000.
- 5) Zarb GA, Albrektsson T: Towards optimized treatment outcomes for dental implants. *J Prosther Dent*, 80: 639-640, 1998.
- 6) Branemark P-I, Zarb G, Albrektsson T: *Tissue-Integrated Prostheses: Osseointegration in Clinical Dentistry*. Chicago: Quintessence, :11-17,1985.
- 7) Chaushu G, Chaushu S, Tzohar A, Dayan D. Immedial loading of single tooth implants; immediate versus non immediate implantation. A clinical repory. *Int J Oral Maxillofac Implants*, 16: 267-272, 2001.