

Endoscopic-Assisted Open Reduction and Internal Fixation (EAORIF) for Condylar Fracture

**Joon-Young Paeng¹⁾, Kang-Min Ahn¹⁾, Hoon Myoung¹⁾, Jin-Young Choi¹⁾, Soon-Jeong Hwang¹⁾,
Soung-Min Kim²⁾, Myung-Jin Kim¹⁾ and Jong-Ho Lee¹⁾**

¹⁾*Department of Oral & Maxillofacial Surgery, Graduate School of Dentistry, Seoul National University, Seoul, Korea*

²⁾*Department of Oral & Maxillofacial Surgery, College of Dentistry, Kang-Neung National University, Kang-Neung, Korea*

Abstract: The endoscopic-assisted approach for the treatment of condylar fracture are a less invasive alternative and overcomes the limited access to the operation field to obtain an accurate reduction and fixation. Nine condylar fracture patients underwent the endoscopic-assisted open reduction and internal fixation through the transoral approach at the department of oral and maxillofacial surgery, Seoul National University Dental Hospital. The endoscope was inserted through an intraoral incision and the reduction of fracture fragment was performed via a transbuccal approach with two transcutaneous stab incisions. Five patients showed anatomic reduction without any complications. Three patients, whose fracture site was fixed with a single plate, showed fractured condylar segment displacement during the follow-up period and one of them resulted in postoperative malocclusion. No patient had any facial nerve damage.

Keywords: subcondylar fracture, endoscopy, open reduction

Introduction

Controversy about the treatment protocol for condylar fracture has a long history in oral and maxillofacial traumatology. Various treatment options have been described for condylar fractures, including closed reduction and open treatment with a variety of surgical approaches.

However, surgical treatment is not unanimously accepted by all surgeons as the first choice of condylar fracture treatment. The anatomical limitation for the approach due to the facial nerve makes the approach and gain of surgical field difficult. To overcome this limitation of open surgery, the endoscopy assisted approach for subcondylar fracture has been developed technically under the concept of "minimally invasive surgery"^{1,2)}. Using an endoscope, superior visibility can be obtained in the condylar area with limited exposure. This enables a transoral open reduction of subcondylar fractures with more predictable results.

Patients and Methods

Nine patients with condylar neck or subcondylar fracture underwent open reduction and internal fixation with the assistance of an endoscope under general anesthesia at the department of oral and maxillofacial surgery, Seoul National University Dental Hospital.

Surgical Procedures;

A 4.0-mm 30-degree rigid telescope (Stryker Endoscope, CA, USA) was used. An intraoral incision of about 2cm was made along the buccal vestibule similar to that performed in bilateral sagittal split osteotomy. Temporary intermaxillary fixation was done with rubber elastics. After reduction of the fractured segment, elastic fixation was changed to wire fixation.

Then internal fixation of the bone fragment was performed through the transcutaneous buccal approach. First, the most proximal hole of the 4-hole 2mm-thick miniplate was drilled and secured with a screw for easy manipulation and reduction of the

fractured fragment. After that, the distal holes of the plate were secured with screws. After surgery, no intermaxillary fixation was applied. Elastic guidance to assist in the training of the occlusion for the early recovery was applied for 1 to 2 weeks depending on the postoperative occlusal condition.

Results & Discussion

Five subcondyle fractures, in which two 4-hole miniplates were used, showed anatomical fracture reduction without any complications such as malunion, wound problems, infection, or nerve damages. They recovered their maximum mouth opening two weeks postoperatively. However, in the condylar neck fracture cases (two bilateral and one unilateral condylar neck fracture), only one 4-hole mini- or microplate was used due to inadequate space for positioning of two plates. In such instances, there was high incidence of plate deformation causing displacement of the reduced condylar fragment during follow-up periods (three out of 4 condylar neck fracture cases). Among them, one case showed overt malocclusion which required re-operation. In our experience, condyle fractures fixed with a single miniplate or microplates showed unstable results especially in unfavorable cases such as both condylar fracture. Fixation with 2 miniplates is recommended for subcondylar or condyle neck fracture^{3,4)}. The first plate is always placed along the posterior-lateral border of the ramus. The second plate is placed along the anterior part of the condylar neck.

Although surgical approaches for the endoscopy assisted treatment of subcondylar fracture can be performed either intraorally or from the submandibular approach, or both, the intraoral approach is considered as more favorable because there is no scar visible and no risk of facial nerve damage. However, in severely dislocated and comminuted fractures, the extraoral approach for the endoscopic-assisted treatment of condylar fracture is indicated, especially in fractures with medial override²⁾.

In spite of the advantages of endoscopic-assisted repair of subcondylar fractures, it still has limitations to cover all types of condylar fractures. Intracapsular condylar head fractures have a risk of avascular necrosis after open reduction. In cases of highest level of neck fractures, a predictable amount of bone is not always available to permit the placement of 2 screws in the segment⁵⁾.

Correspondence to Jong-Ho Lee, Department of Oral & Maxillofacial Surgery, Graduate School of Dentistry, Seoul National University, 28-2, Yeongun-Dong, Chongro-Ku, Seoul, 110-460, Korea. leejongh@plaza.snu.ac.kr

Severely medially displaced fragment is more challenging to reduce within the narrow space under the endoscopic view. In addition, fractures with multiple segments may need more delicate skill and longer operation times.

- 1) Troulis MJ, Kaban LB. J Oral Maxillofac Surg 59:503-509; 2004.
- 2) Schon R. Int J Oral Maxillofac Surg 31:237-243; 2002
- 3) Choi BH. J Oral Maxillofac Surg 59:734-737; 2001.
- 4) Choi BH. J Craniomaxillofac Surg 27:109-112; 1999.
- 5) Haug RH. J Oral Maxillofac Surg 59:370-375; 2001.

References

Table 1. Patients' characteristics and results

Patients	Age	Sex	Fracture site	Fracture Pattern*	Fixation	Results
1	26	F	Rt. Subcondyle	Displacement / lateral override	2 miniplates	good
2	45	F	Rt. Subcondyle	Displacement / lateral override	2 miniplates	-good
3	58	M	Both condylar neck	Rt. : Displacement / comminuted Lt. : Deviation	Rt :1 miniplate	Condylar displacement
4	36	M	Both condylar neck	Both : displacement	Rt: 1 microplate	Condylar displacement Malocclusion
5	36	F	Rt. Condylar Head Lt. Condylar Neck	Rt: Dislocation Lt. : Dislocation	Rt. Fragment removal Lt. : 2 miniplates	good
6	31	M	Lt. subcondyle	Displacement / lateral override	2 miniplates	good
7	41	F	Lt. Condylar neck	Dislocation	1 microplate	Condylar displacement
8	35	F	Rt. Subcondylar	Displacement / lateral override	2 miniplates	good
9	16	M	Rt. Subcondyle	Deviation	2 miniplates	Malpositioned fixation No clinical symptom

* Fracture pattern –MacLennan’s classification

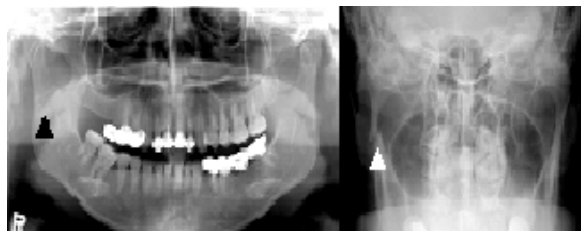

Figure 1. Preoperative panoramic and modified Towne’s radiograph showing right subcondylar fracture (arrow)

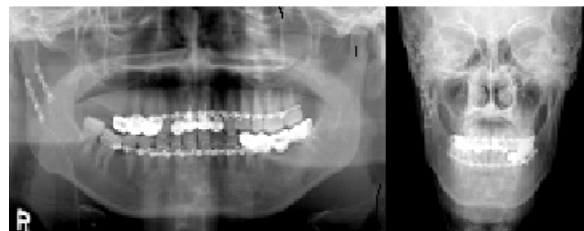


Figure 3. Postoperative panoramic and PA radiograph. Anatomical reduction and fixation was achieved.

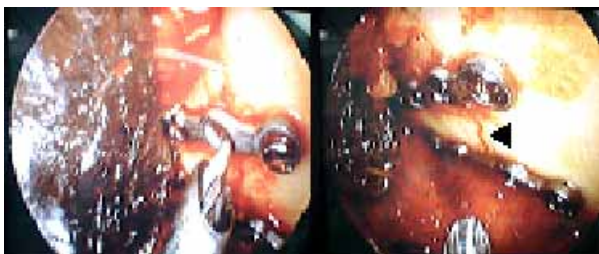

Figure 2. Fixation as visualized through the endoscope. Black arrow points to the fracture line.

“This study was supported by a grant of the 21C New Frontier R&D Project (M105KO010001-05K1501-00110)”