

Histological Characteristics of Mandible in Fetal Mice

Takako Shimizu

Matsumoto Dental University Graduate School of Oral Medicine, Shiojiri 399-0781, Japan

Abstract: It is well known that mandible bone is formed by intramembranous ossification. Mandible condyle cartilage and angular cartilage are recognized as secondary cartilage, which differs from primary cartilage in morphological and biochemical organization. These are interesting research subjects from a clinical point of view as they compose the TMJ. We examined the mandible, mandible condyle cartilage and angular cartilage of fetal mice using histology, histochemistry, immunohistochemistry and *in situ* hybridization techniques. Chondroid bone and chondrocyte like cells were observed during the mandible osteogenic process. The characteristics of mandible condyle cartilage and angular cartilage were slightly different from those of normal physiological articular cartilage.

Key words: mandible bone, chondroid bone, mandible angular cartilage, mandible condyle cartilage.

Introduction

It is well known that mandible bone is formed by intramembranous ossification mode. Human developing mandible has chondrocyte-like cells, shown in hematoxyline & eosin (HE), stained histological specimens (Figure 1). In this figure, chondrocyte-like cells were observed during the mandible osteogenic process. This phenomenon is described as “chondroid-bone” in Orban’s oral histology and embryology¹⁾. But there is no further description in other histology and embryology textbooks. This phenomenon shows slightly different from direct bone ossification patterns. So we are interested in the characteristic of mandible bone formation.

Nature of developmental mandible bone

We investigated the nature of developmental mandible bone using fetal and young immature ddY mice. Immunohistochemically, bone forming cells showed positive reaction for both type 2 collagen and osteocalcin. On the second neonatal day, they showed a metachromasia to toluidine blue (TB) (Figure 2). These results indicate that some bone forming cells have characteristics of cartilage cells, and that chondroid bone formation intermingles with osteogenesis in the early phase of bone formation²⁾.

Characteristics of mandible condyle and angle cartilage

It is well known that condyle and angle cartilages are classified as secondary cartilage and are replaced by bone tissue through the endochondral ossification mode. Histologically, mouse mandible condyle and angle cartilage development started as a coagulation of mesenchymal cells on the 15th fetal day. On the 16th fetal day, cells in the central portion were coagulated, showed a metachromasia reaction to TB. After the 17th fetal day, endochondral ossification occurred with invasion of capillaries, and perichondral ossification occurred in the periphery of the cartilage mass. On the 18th fetal day, endochondral ossification occurred in the periphery of the cartilage mass. Generally, in articular cartilage, type 2 collagen is expressed through all layers. Type 1 collagen is

expressed only in bone tissue. Furthermore, osteopontin (OPN) appears in bone tissue and a part of hypertrophic cell. Immunohistochemistry showed type 2 collagen positive chondrocytes at the 16th fetal day. After the 17th day almost all proliferating chondrocytes were stained strongly. The positive reaction to type1 collagen was detected in proliferating chondrocytes through the examination period (Figure3). The positive reaction to OPN as well as to type 1 collagen and OPN³⁾ was detected in proliferating chondrocytes through the examination period.

These results suggest that these cartilage cells are slightly different from other cartilage⁴⁾. Therefore, we believed that the developing mechanism is also different from other cartilage.

Morphogenesis regulation factors

Recently various studies have been published about the relationship between cartilage formation and morphogenesis factors. We consider that morphogenesis regulation factors play an important role in developing a mandible condyle cartilage. We therefore investigated the distribution of Notch1 and Math1, with osteopontin as control, and had new findings, so we have prepared a manuscript and it submitted to the journal “Angle Orthodontist”. It will be published in the Journal “Angle Orthodontist” in the November issue⁵⁾. On the basis of the cellular morphological changes, mandible condyle cartilage is histopathologically composed of four different layers⁶⁾. OPN was distinct in almost all layers, and it was most distinct in the cytoplasm Figure 4 Notch1 was present in the hypertrophic layer only. Math1 was distributed in the hypertrophic layer and particularly in the proliferative layer. OPN was detected throughout almost all layers. Notch1 was present in the hypertrophic layer only. There was no detectable immunoreaction for Notch1 in the upper three layers. Math1 was distributed in the hypertrophic layer and partially in the proliferative layer. Therefore, present immunohistochemical results of mandible condyle cartilage show that the characteristics of proliferating mandible condyle cartilage are nearly the same as those of mandible angular cartilage, and slightly different from normal physiological articular cartilage.

Conclusion

Chondroid bone and chondrocyte-like cells were observed during the mandible osteogenic process. The characteristics of condyle cartilage and angle cartilage are slightly different from

Correspondence to Takako Shimizu DDS, Matsumoto Dental University Graduate School of Oral Medicine Hard Tissue Pathology Unit,1780 Hirooka-Gobara, Shiojiri, 399-0781 Japan, E-mail: tshimizu@po.mdu.ac.jp, Phone & Fax: +81-263-51-2035

other cartilage.

References

1. Bhaskar SN. Orban's Oral Histology and Embryology, 9th ed, 240-260, CV Mosby Co, St Louis. 1980.
2. Kimura A. Matrix protein production and gene expression in bone forming cells on mandible bone formation of mouse. J Tokyo Dent Coll Soc 103: 335-345, 2003.
3. Kawakami T, Shimizu M and Shimizu T. Immunohistochemical characteristics of developing mandible angle in fetal mice. Eur J Med Res (in press).
4. Ishiwari Y, Nagatsuka H, Inoue M and Nagai N. Localized expression of type I, II, and X collagen genes in the mandibular condyle of immature mice. Oakayama Dent J 723: 688-698, 1999.
5. Shimizu T, Tsujigiwa H, Nagatsuka H, Okafuji N, Kurihara S, Nagai N, and Kawakami T. Expression of Notch1 and Math 1 in mandibular condyle cartilage in neonatal mice. Angle Orthodont 75: 787-789, 2005.
6. Lee K, Deeds JD, Chiba S, U-no M, Bond AT and Segre GV. Parathydo Hormone induces sequential c-fos expression in bone cells in vivo: In situ localization of its receptor and c-fos messenger ribonucleic acids. Endocrinology134: 441-450, 1994.

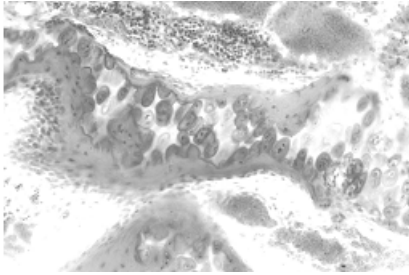


Fig.1: Human developing mandible (HE, from Prof Sahara N, Matsumoto Dental University, 200X)

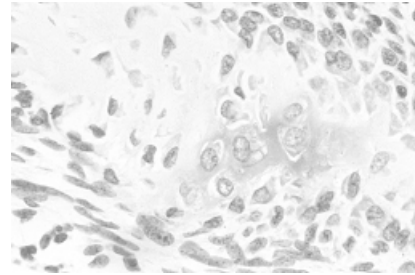


Fig.3: The distribution of Type I (Mandible angle, 250X)

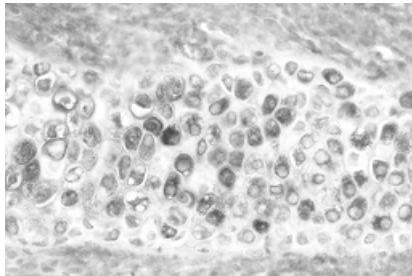


Fig.2: The reaction to TB (Mandible bone, 300X)

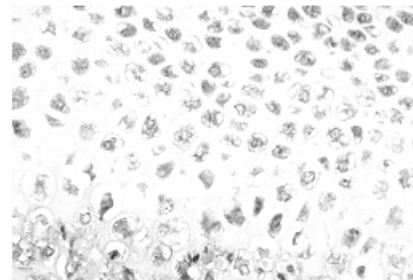


Fig.4: The distribution of OPN (Mandible condyle, 250X).