

## Management of Trauma of Primary Tooth: Report of Intrusion Case

Ryouko Hirata<sup>1)</sup>, Youko Hayashi<sup>2)</sup>, Ryujirou Mizuno<sup>2)</sup>, Jyunnji Suzuki<sup>2)</sup>, and Katsuyuki Kosai<sup>2)</sup>

<sup>1)</sup> Pediatric Dental Clinic, Hiroshima University Hospital, 2-3, Kasumi 1-chome, Minami-ku, Hiroshima, Japan, 734-8553

<sup>2)</sup> Department of Pediatric Dentistry, Graduate School of Biomedical Sciences Hiroshima University

**Abstract:** From the analysis of 11 cases, an intruded primary tooth may be expected to re-erupt without intervention, and the outcome is worse in cases that undergo repositioning and splinting. Therefore, in the management of infants aged 1 to 3 years, observation of clinical course is the first choice in our department. The effect on the subsequently replacing permanent tooth will be studied in the future.

### Introduction

This report focuses on intrusion among luxations commonly seen in dental traumas. We analyzed 11 cases of intrusion of the primary tooth presented at the Department of Pediatric Dentistry, Hiroshima University Hospital. From this series, we report the detailed clinical courses of three cases.

### Case Report

#### Case 1

An 18 month-old boy presented with complete intrusion of A (Fig. 1) caused by trauma to the maxillary anterior tooth region. The patient was managed by observation of the clinical course. At 4 months after injury, re-eruption was observed to the same extent as the contralateral side. At 11 months after injury, discoloration of the crown of A was observed and treatment for infected root canal was conducted. At 3 years and 10 months after injury (5 years and 4 months of age), physiological root resorption was observed (Fig. 2).

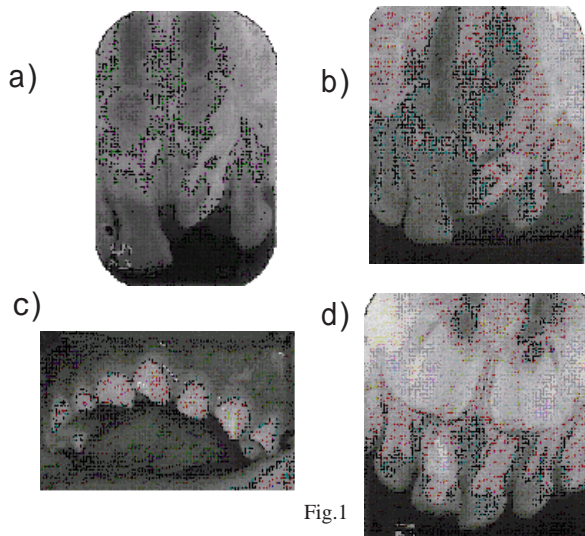


Fig.1

#### Case 2

A 14 month-old girl presented with complete intrusion of A caused by a fall that occurred 4 days before presentation. The patient was managed by observation of the clinical course. At around 10 days after injury, re-eruption of A was observed. At 3 months after injury, re-eruption to the same degree as the contralateral side was observed, although rotation was present in A. At 6 months after injury, root resorption was observed (Fig. 4). At 15 months after trauma (2 years and 5 months of age), there

was no remarkable abnormality.

#### Case 3 (repositioning and splinting)

A 23 month-old boy presented with incisal fracture and approximately 1/2 crown intrusion of A (Fig. 5) caused by trauma to the maxillary anterior tooth region. Movement was observed in A. Treatment included repositioning of A and wire splinting of C C. On day 11 after injury, discoloration of A was observed. On day 25, splinting was removed. At 4 months after injury, since a fistula was formed in A, and the A A root region appeared

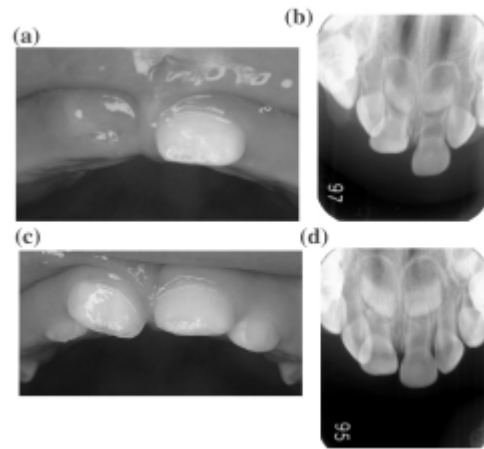


Fig.3

